ELSEVIER

Neurobiology of Aging, Vol. 17, No. 2, pp. 249–257, 1996

0197-4580/96 $15.00 + .00

0197-4580(95)02062-4

Carboxy Terminal of β-Amyloid Deposits in Aged Human, Canine, and Polar Bear Brains

TINA L. TEKIRIAN,* GREGORY M. COLE,† MICHAEL J. RUSSELL,‡ FUSHEN YANG,† DAVID R. WEKSTEIN,* ELA PATEL,* DAVID A. SNOWDON,* WILLIAM R. MARKESBERY* AND JAMES W. GEDDES*[1]

*Alzheimer's Disease Research Center, Sanders-Brown Center on Aging, 209 Sanders-Brown Building, University of Kentucky, Lexington, KY 40536
†Geriatrics, Sepulveda VA Hospital, Sepulveda, CA 91343
‡Anesthesiology, School of Medicine, University of California, Davis, CA 95616

Received 17 April 1995; Revised 10 July 1995; Accepted 13 October 1995

TEKIRIAN, T. L., G. M. COLE, M. J. RUSSELL, F. YANG, D. R. WEKSTEIN, E. PATEL, D. A. SNOWDON, W. R. MARKESBERY AND J. W. GEDDES. *Carboxy terminal of β-amyloid deposits in human, canine, and polar bear brains.* NEUROBIOL AGING **17**(2) 249–257, 1996.—Immunocytochemistry, using antibodies specific for different carboxy termini of β-amyloid, Aβ40 and Aβ42(43), was used to compare β-amyloid deposits in aged animal models to nondemented and demented Alzheimer's disease human cases. Aged beagle dogs exhibit diffuse plaques in the absence of neurofibrillary pathology and the aged polar bear brains contain diffuse plaques and PHF-1–positive neurofibrillary tangles. The brains of nondemented human subjects displayed abundant diffuse plaques, whereas the AD cases had both diffuse and mature (cored) neuritic plaques. Diffuse plaques were positively immunostained with an antibody against Aβ42(43) in all examined species, whereas Aβ40 immunopositive mature plaques were observed only in the human brain. Anti-Aβ40 strongly immunolabeled cerebrovascular β-amyloid deposits in each of the species examined, although some deposits in the polar bear brain were preferentially labeled with anti-Aβ42(43). β-Amyloid deposition was evident in the outer molecular layer of the dentate gyrus in the aged dog, polar bear, and human. Within this layer, Aβ42 was present as diffuse deposits, although these deposits were morphologically distinct in each of the examined animal models. In dogs, Aβ42 was cloud-like in nature; the polar bear demonstrated a more aggregated type of deposition, and the nondemented human displayed well-defined deposits. Alzheimer's disease cases were most frequently marked by neuritic plaques in this region. Taken together, the data indicate that β-amyloid deposition in aged mammals is similar to the earliest stages observed in human brain. In each species, Aβ42(43) is the initially deposited isoform in diffuse plaques.

β-Amyloid Dogs Polar bears Humans

β-AMYLOID (Aβ) is often associated with two Alzheimer disease-related lesions: diffuse and neuritic senile plaques, and cerebrovascular angiopathy (CVA) (6,41). These lesions are also present in the brain of aged mammals including dogs, bears, and primates (7,23,33). In this study, antibodies specific for the carboxy terminal of Aβ were used to compare the deposits present in the aged mammals with those observed in Alzheimer's disease (AD) and in nondemented elderly individuals.

There are numerous neuritic plaques in the AD cortex. These plaques are also present, albeit to a lesser extent, in normal elderly individuals (44). Such plaques can be subclassified as immature or mature. Immature neuritic plaques contain Aβ fibrils intermixed with swollen neurites in a well-defined spherical plaque (50). Mature, dense-cored plaques are surrounded by a wreath of dystrophic neurites; these entities are further defined by the presence of apolipoprotein E (APOE) as well as reactive astrocytes (18,30). Diffuse plaques are amorphous in nature and not associated with swollen neurites or glial components (32). In Down syndrome, diffuse plaques precede the appearance of neuritic plaques and neurofibrillary tangles (22). Diffuse plaques might be precursors of neuritic plaque formation (22). However, each subtype may be formed through independent mechanisms (9,38). In addition to plaques, Aβ is often deposited in the leptomeninges, particularly within the tunica media of small arteries and veins (21). Whether cerebrovascular amyloidosis (CVA) is a condition that coexists with AD or is a separate entity, in and of itself, is under debate (47).

Aβ, a 39–43 amino acid peptide, is proteolytically derived from a β-amyloid precursor protein (βAPP), which has a large extracellular N-terminus, a single membrane spanning region, and a short C-terminus (35). In AD, there is heterogeneity of the Aβ amino and carboxyl termini. At the amino terminus, Aβ can begin at the first amino terminal residue ($A\beta_{N1}$) or at a modified third amino acid where glutamate is converted to pyroglutamate, $A\beta_{N3(pE)}$ (25,34). At the carboxyl terminus, conflicting reports have suggested that Aβ42 (24,31) or Aβ40 is the major species (25) present in parenchymal Aβ deposits. Biochemical studies suggest that Aβ40 predominates in cerebrovascular amyloid (24,

[1] To whom requests for reprints should be addressed.

TABLE 1

HUMAN, POLAR BEAR, AND BEAGLE DOG CASES EXAMINED

Case	Species	Age	Sex	MMSE	Diagnosis
H1	Human	84	F	26/30	Nondemented, abundant diffuse plaques, CVA
H2	Human	95	F	30/30	Nondemented, abundant diffuse plaques, CVA
H3	Human	78	F	14/30	Alzheimer's disease, CVA
H4	Human	77	M	NA	Alzheimer's disease, CVA
H5	Human	71	F	15/30	Alzheimer's disease, no CVA
H6	Human	78	F	NA	Alzheimer's disease, CVA
PB1	Polar Bear	35	M		Diffuse plaques and NFTs
PB2	Polar Bear	36	F		Diffuse plaques and NFTs, CVA
D1	Beagle Dog	14.5	F		Diffuse plaques, CVA
D2	Beagle Dog	16	F		Diffuse plaques, CVA
D3	Beagle Dog	17	M		Diffuse plaques, CVA
D4	Beagle Dog	14	M		Few diffuse plaques, CVA
D5	Beagle Dog	14	F		Diffuse plaques, CVA

Abbreviations: CVA, cerebrovascular β-amyloid deposits; MMSE, Mini-Mental examination score; NA, not available; NFTs, neurofibrillary tangles.

31). In cerebrospinal fluid, Aβ40 is the major isoform (37). The secretion of Aβ40 is greater than that of Aβ42 in human neuroblastoma (M17) cells transfected with βAPP (43). Transfection of the neuroblastoma cells with βAPP717 mutants linked to familial AD results in increased release of Aβ42(43). The significance of the various isoforms is at least twofold. Polymerization into amyloid fibrils is more rapid with 1–42 than with 1–40 (15,29), and may be even more rapid with 3(pE)-42 (34). Secondly, the Aβ isoform-dependent aggregation state directly affects amyloidogenic toxicity (5,28). The proximity of a number of FAD mutations to Aβ suggests that aberrant βAPP processing at the C-terminus and/or N-terminus could play an important role in AD (35). In sporadic AD cases, monoclonal antibodies specific for the carboxyl terminus of Aβ1–40 or 1–42(43) demonstrate that Aβ42(43) is present in both diffuse and neuritic plaques, whereas Aβ40 is found in a subset of primarily mature (cored) plaques (14,20,52). Additionally, antibodies against Aβ42(43) and Aβ40 immunostain CVA in meningeal vessels. In familial AD cases with the βAPP717 mutation (Val to Ile), a similar predominance of Aβ42(43) over Aβ40 immunopositive plaques is observed (14). In Down syndrome brains, the appearance of Aβ42(43) immunostained plaques precede the appearance of Aβ40-positive senile plaques (13). This has led to the suggestion that AD may be initiated by the deposition of Aβ42 (53).

The amino acid sequence of the 43 amino acid Aβ peptide is identical in dogs, polar bears, monkeys, and humans (16). Antibodies against human Aβ crossreact with plaque and CVA deposits in aged dogs, bears, and primates (36). Although β-amyloid deposits and CVA have been observed in the human, aged primate (36), bear (7), and dog brain (49), the extent of AD-like pathology

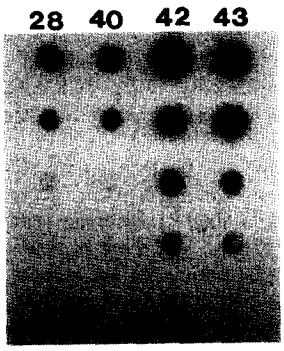

FIG. 1. A dot blot illustrating the specificity of monoclonal 7A3 made for Aβ42 (43) peptide. Aβ1–28, 1–40, 1–42, or 1–43 (10 ng) was absorbed onto 0.22 μM Immobilon membrane and dot blotted with serial 1:2 dilutions of 7A3 ascites starting at 1:400. The ascites was produced from the same clone as the hybridoma. Aβ1–28 defines background staining, because this peptide does not overlap with the Aβ37–42.

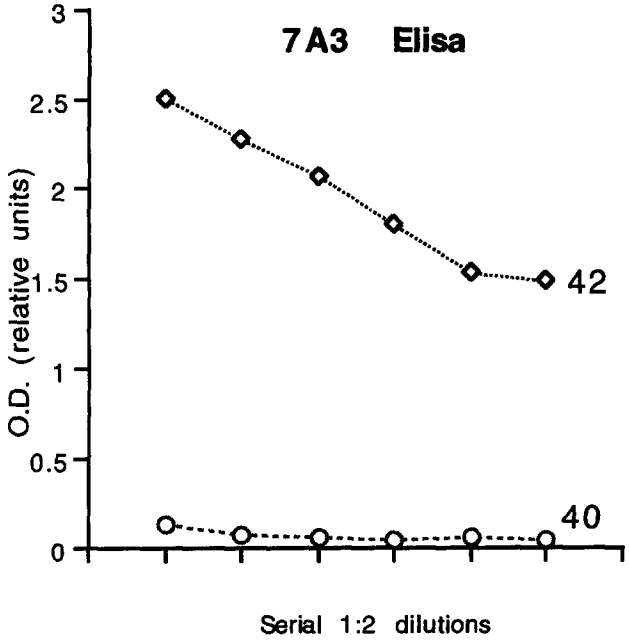

FIG. 2. ELISA demonstrates that 7A3 recognizes the C-terminus of Aβ1–42 but not 1–40. Synthetic peptides Aβ34–40 and 37–42 conjugated to ovalbumin were plated at 300 ng, blocked and reacted with 1:2 serial dilutions of 7A3 hybridoma followed by detection with alkaline phosphatase conjugated antimouse IgG.

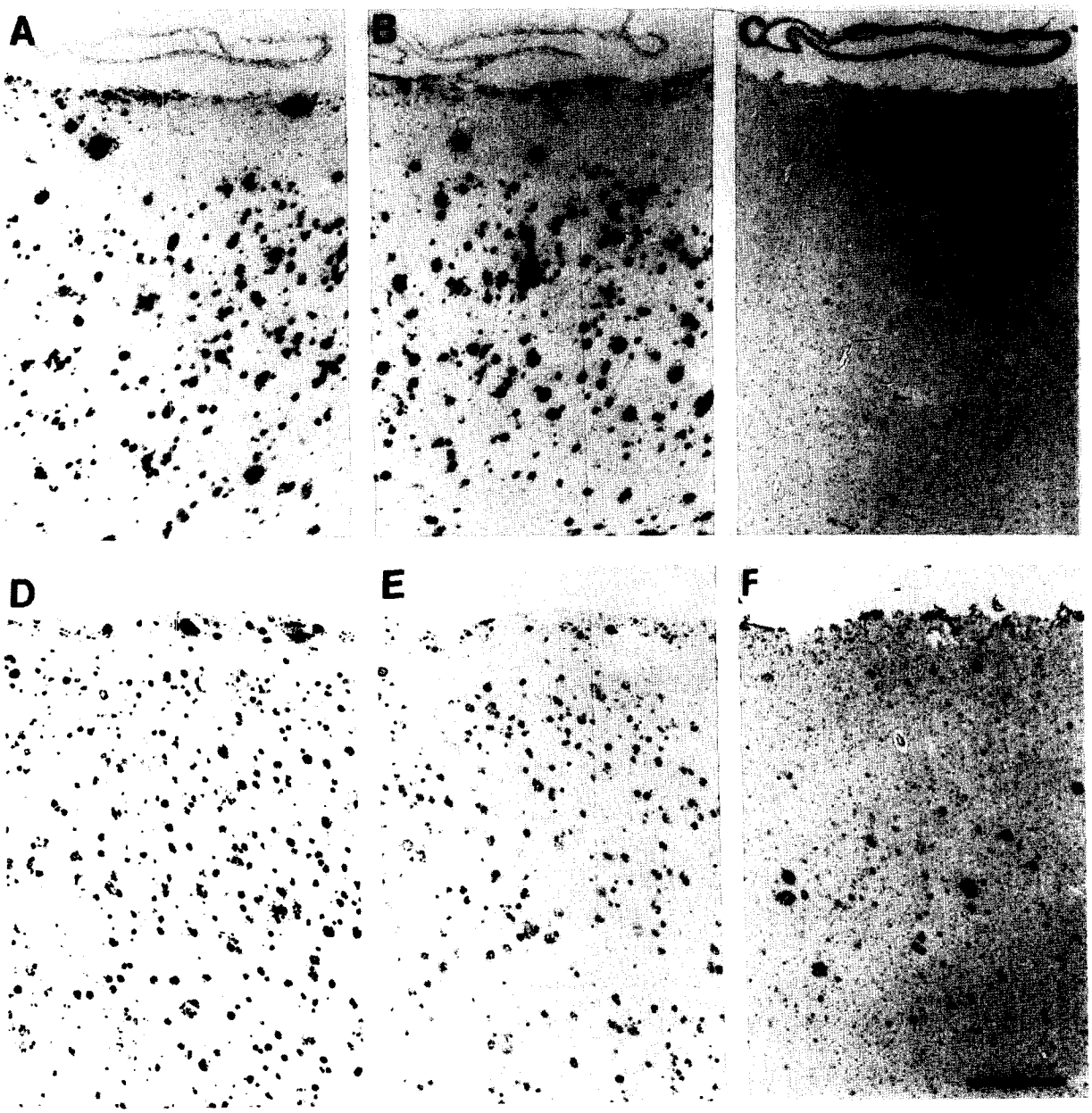

FIG. 3. Differential staining of β-amyloid deposits in human brain by *C*-terminal specific antibodies. In a nondemented 84-year-old female, in which diffuse plaques were abundant, 10D5 (A) and 7A3 (B) immunostained the parenchymal β-amyloid deposits in a similar fashion, but staining was rarely observed with anti-Aβ40 (C). In the leptomeninges, anti-Aβ40 strongly immunostained the β-amyloid deposits, whereas these were faintly labeled with 10D5 and 7A3. In a 71-year-old male with AD, both diffuse and neuritic plaques were strongly immunostained in the superior temporal gyrus with the 10D5 antibody, directed against Aβ1–16 (D). The 7A3 antibody (anti-Aβ42) produced a similar pattern of immunostaining (E). In contrast, anti-Aβ40 labeled only a subset of Aβ deposits, primarily mature and compact plaques (F). A–C represent parahippocampal gyrus, D–F are from the superior temporal region. Scale bar = 200 μm (F).

varies among these species. Aged dogs develop diffuse plaques and rarely exhibit neuritic plaques and neurofibrillary tangles (8, 33). Aged bears develop both neuritic (senile) plaques and neurofibrillary tangles (7). Severity of the β-amyloid deposits in the aged animals more closely resembles normal human aging than AD.

The purpose of this study was to use antibodies specific for the C-terminus of β-amyloid to examine Aβ deposits in aged mammals, with and without neurofibrillary pathology (beagle dog vs. polar bear). The results are compared to those obtained in the nondemented and demented (AD) human brain.

METHOD

Aged Canine Tissues

The aged beagle dog brain tissues examined in this study (Table 1) were obtained from the National Radiobiology Archives, as previously described (8,33). The animals received low levels of strontium-90 in their diet, but their longevity did not significantly differ from those of the control group. A previous study indicated a similar diffuse plaque distribution for this group and for those animals that were not exposed to radiation (33). The beagles either died of natural causes or were euthanized, due to terminal illness

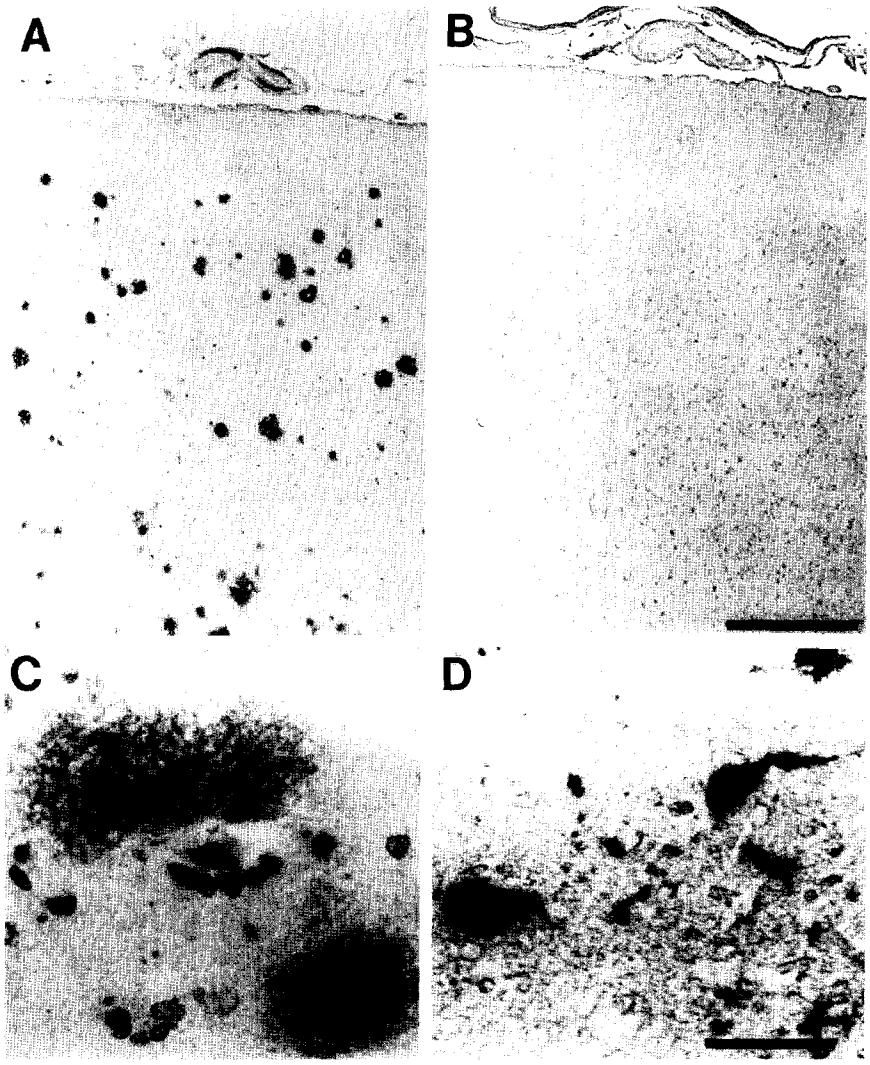

FIG. 4. β-Amyloid deposits and neurofibrillary tangles in the aged polar bear. In a 36-year-old female polar bear, diffuse plaques were abundant in frontal cortex. In addition, Aβ deposits were evident in the leptomeninges. These were both strongly immunostained with 7A3 (A) but not with anti-Aβ40 (B). An enlarged view of a 7A3 immunostained diffuse plaque is illustrated in (C). This section was also stained with hematoxylin to indicate cell bodies, and photographed using a blue filter to increase the contrast of the Aβ immunostaining over the hematoxylin. Neurofibrillary tangles were also present in the two polar bears examined, and were immunostained with the PHF-1 antibody (D). Although one tangle in this figure shows prominent staining of the apical dendrite, this was rarely observed and the tangles were not accompanied by neuropil threads. Scale bars = 200 μm (B) and 50 μm (D).

or chronic pain. Necropsy included thorough gross and microscopic pathologic evaluations of all major organ systems. Brain tissue samples were immersion-fixed in 10% neutral-buffered formalin. For this study, tissue was obtained from the hippocampal formation, parahippocampal gyrus, and temporal cortex, paraffin-embedded, then sectioned at 10 μm.

Aged Polar Bears

The aged polar bears examined in this study (Table 1) were obtained from a Toledo, OH, zoo. One bear, a 35-year-old male, was euthanized due to back injury. The second bear was also euthanized (36 years old, renal disease complications). At autopsy, the brains were removed and placed in 10% neutral buffered formalin. Subsequently, hippocampal formation and temporal cortex blocks were paraffin-embedded and sectioned at 10 μm.

Human Tissues

Six human brains, from subjects ranging between ages 71–95, were obtained from the brain repository of the University of Kentucky Alzheimer's Disease Research Center (ADRC) (Table 1). At autopsy, brain specimens were placed in 10% buffered formalin. After fixation, the tissue was paraffin embedded and sectioned at 10 μm. Four of the subjects had histories of progressive dementia and neuropathologic evaluation confirmed diagnoses of Alzheimer's disease using established criteria (17). Two individuals were not demented, as determined by neuropsychological testing (Table

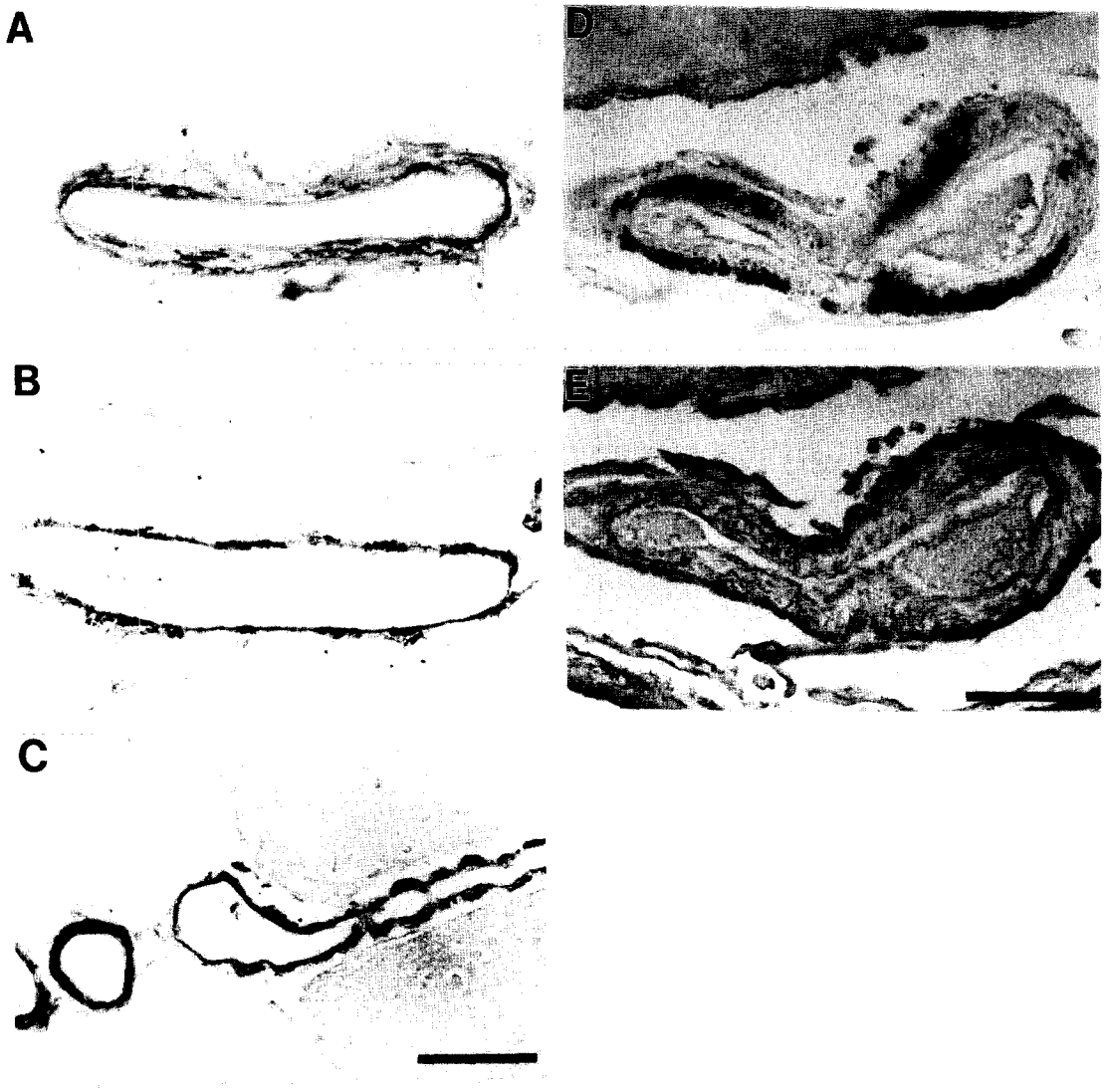

FIG. 5. Leptomeningeal β-amyloid deposits in the aged dog and polar bear. In the aged dog, leptomeningeal Aβ was detected with the 7A3 (A) anti-Aβ40 (B) and 10D5 (C) antibodies. In an aged polar bear, one vessel was strongly labeled by 7A3 (D), whereas only nonspecific background staining was observed with anti-Aβ40 (E). Scale bar = 200 μm.

1); however, neuropathologic evaluation revealed numerous diffuse plaques without a significant number of neurofibrillary tangles. Atherosclerosis of moderate severity was also observed in these two individuals. Areas examined included hippocampus, amygdala, as well as the superior and middle temporal cortices.

Histology

Tissue sections were deparaffinized and stained by the modified Bielschowsky method and Thioflavin-S techniques (51). For immunocytochemistry, the slides were deparaffinized, then pretreated with formic acid (19), pepsin (10 min), and 3% H_2O_2 in 10% methanol. Sections were incubated with primary antibody overnight, at room temperature. Primary antibodies included monoclonal anti-Aβ42(43) (7A3, 1:20), monoclonal anti-Aβ1–16 (10D5, 1:100), monoclonal PHF-1 (1:100), or polyclonal anti-Aβ40 (1:1000). With the exception of 7A3, all of the antibodies have been completely characterized (12,20,48,52). 7A3 is a monoclonal antibody generated against Aβ37–42. The procedures that were used to produce 7A3 have been previously described with regard to the production of monoclonal antibody specific for the C-terminus of β-amyloid (52). Characterization of 7A3 is presented in the Results section.

Negative controls for immunolabeling included omission of the primary antibody and substitution of primary antibody with normal serum as well as preadsorption of each antibody with Aβ 1–40 and 37–42 peptide (20 μg/ml). Sections were incubated with the appropriate biotinylated secondary antibody (goat antirabbit IgG or horse antimouse IgG, Vector Laboratories, Burlingame, CA) followed by avidin–biotin complex (ABC Elite Kit, Vector). Color visualization was attained with diaminobenzidine (Sigma) or metal-enhanced diaminobenzidene (Pierce, Rockford, IL). Some sections were also counterstained with hematoxylin. All sections were examined and photographed on an Olympus BH-2 microscope.

RESULTS

The 7A3 antibody was characterized using dot blot, ELISA, and preadsorption with Aβ37–42 and Aβ1–40. The dot blot (Fig.

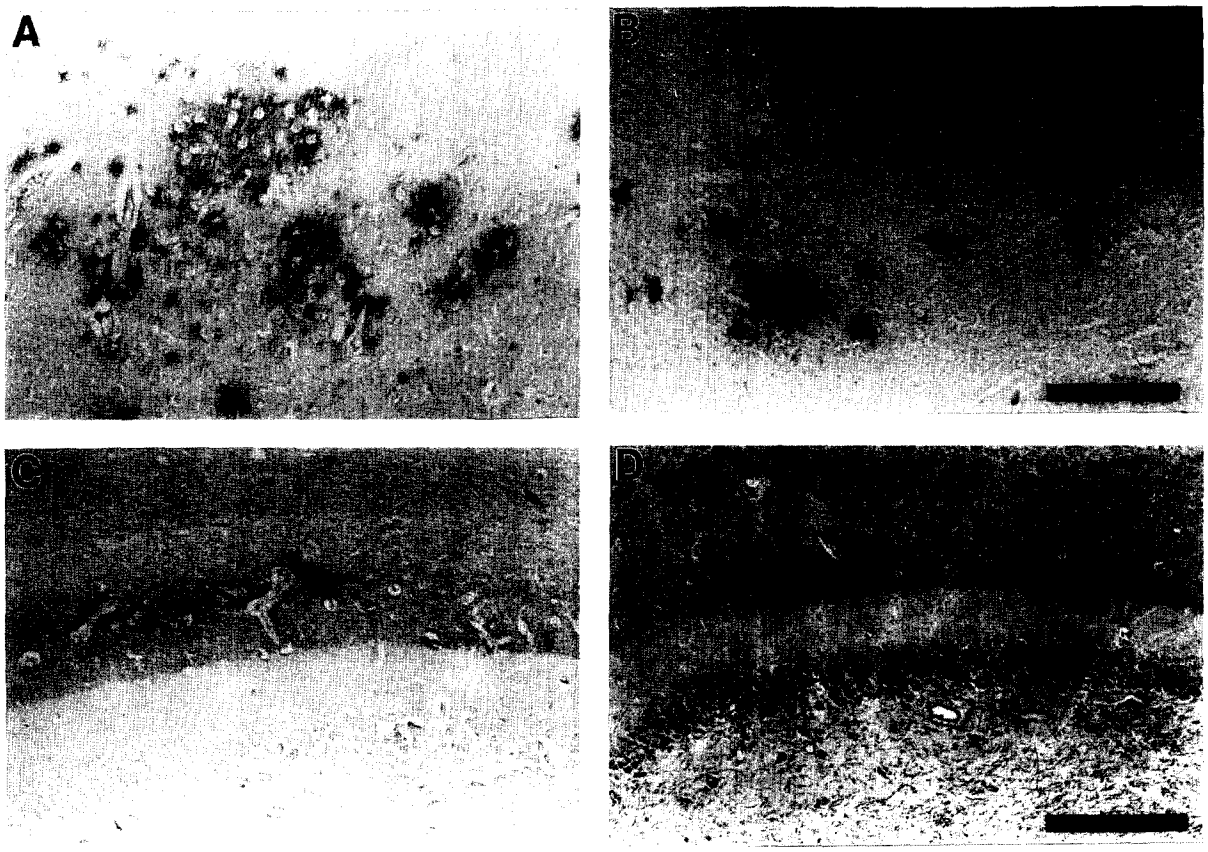

FIG. 6. β-Amyloid deposits in the aged beagle dog. The 7A3 (anti-Aβ42) antibody immunostained diffuse plaques at the parahippocampal gyrus in an aged beagle dog (14.5 years of age, female) (A). These deposits were also labeled by 10D5 but not by anti-Aβ40 (not shown). In contrast, vascular and perivascular amyloid deposits were immunolabeled with anti-Aβ40 (B). A cloud of Aβ was evident throughout the outer molecular layer of the dentate gyrus. This cloud was immunostained with 7A3 (C), 10D5 (see Fig. 7), and with Bielschowsky silver stain (D). The scale bar in (B) = 100 μm, the scale bar shown in (D) = 200 μm and also applies to (A) and (C).

1) illustrates that monoclonal antibody 7A3 ascites recognizes Aβ1–42 and 1–43, but not the Aβ1–40 sequence. The ascites was produced from the same clonal cell line used to produce the hybridoma supernatant. 7A3 ascites labels Aβ1–40 only at antibody dilutions that also recognize Aβ1–28. Since Aβ1–28 has no overlap with the Aβ37–42 used to generate the antibody, this represents background staining. At dilutions greater than 1:400, the ascites specifically recognizes Aβ42(43). The ELISA results, obtained using the hybridoma supernatant, verify the specificity of 7A3 for Aβ42 (Fig. 2). The 7A3 hybridoma supernatant was used for immunocytochemistry at a dilution of 1:20. Preadsorption of 7A3 with Aβ37–42 largely abolished immunostaining, although some plaques were very faintly stained (results not shown). Preadsorption of 10D5 and anti-Aβ40 with the same peptide did not alter the pattern of immunostaining. In contrast, 10D5 and anti-Aβ40 immunostaining was greatly diminished following preadsorption with Aβ1–40, but preadsorption with this peptide did not alter the results obtained with 7A3. Together, these results demonstrate the specificity of 7A3 for Aβ42(43), anti-Aβ40 for Aβ40, and 10D5 for both Aβ40 and Aβ42(43).

In both AD subjects and nondemented individuals, the pattern of immunostaining obtained with 7A3 was similar to that obtained with the Aβ1–16 directed antibody 10D5 (Fig. 3). Both antibodies recognized the following morphological subtypes of Aβ deposits: 1) diffuse deposits, 10–200 μm in size, irregularly shaped, faintly immunostained; 2) primitive plaques, 20–60 μm, round, moderately stained, well demarcated; 3) mature (cored) plaques, which were similar to primitive plaques but had a distinct core and halo and were strongly immunostained; and 4) compact deposits, 5–15 μm, no halo, strongly immunostained. The plaques in the nondemented subjects were mainly of the diffuse type, whereas numerous mature and compact deposits were evident in AD cases. In mature (cored) plaques, both the core and halo were immunostained with approximately equal intensity by the 10D5 antibody. In contrast, 7A3 results were more variable, with the core being more strongly stained in some plaques and the halo in others (Fig. 3). 7A3 and 10D5 also recognized cerebrovascular amyloid deposits, which were particularly evident in some leptomeningeal vessels. A polyclonal antibody, highly selective for Aβ40 (anti-Aβ40) (20), recognized a subset of primitive mature and compact plaques, but did not immunostain diffuse plaques (Fig. 3). In mature plaques, the core was intensely labeled and the halo faintly immunostained. Cerebrovascular amyloid was strongly immunostained by anti-Aβ40.

In two aged polar bears, many diffuse plaques were intensely immunostained with the 10D5 and 7A3 antibodies, but were not recognized by anti-Aβ40 (Fig. 4). Consistent with prior observations, in both human and canine brains, diffuse deposits often surrounded several unstained areas that contained morphologically normal neuronal cell bodies (2,8). Cerebrovascular amyloid was present in one of the animals (PB2) and deposits were immunoreactive with 10D5, 7A3, and anti-Aβ40. However, some deposits were strongly immunostained with 7A3 and not with anti-Aβ40 (Figs. 4 and 5). In each of the aged bears, PHF-1 antibody immu-

nostained many neuronal perikarya and some apical dendrites, but infrequently labeled dystrophic plaque neurites and neuropil threads (Fig. 4). The presence of tangles, but lack of neuritic abnormalities, was also revealed with the Bielschowsky stain. Thioflavin S revealed cerebrovascular amyloid, but did not detect diffuse deposits.

Diffuse plaques, present in each of the aged dog brains, were immunostained with 10D5 and 7A3, but not by anti-Aβ40 (Fig. 6). These were faint and amorphous, in contrast to the more compacted β-amyloid diffuse deposits observed in the human and polar bear brain sections. The diffuse clouds were observed in cortical regions of each dog and in the outer molecular layer of the dentate gyrus in four of the five animals (Fig. 6). In two animals (D1 and D4), well-circumscribed parenchymal diffuse β-amyloid deposits were strongly immunostained with 7A3 and 10D5, but faintly recognized by Aβ40 (Fig. 6A). These resembled primitive plaques observed in the human brain, but were not associated with dystrophic neurites, as determined using PHF-1 immunocytochemistry and the Bielschowsky stain. Moreover, these deposits were not revealed with Thioflavin S. Cerebrovascular amyloid deposits were present in each of the aged dogs examined, and were immunostained by the 7A3, 10D5, and anti-Aβ40 antibodies (Figs. 5 and 6B).

β-Amyloid deposits were observed in the dentate gyrus outer molecular layer (but not the inner molecular layer) in each of the species examined and illustrate the species differences observed in this study (Fig. 7). Deposits appear as a diffuse cloud in the aged beagle dog brain, as more condensed deposits in the aged polar bear, and as mature cored and compact plaques in AD. In some aged beagle dog brains, Bielschowsky stain has revealed Aβ deposits in the dentate gyrus outer molecular layer, which resemble the more aggregated state observed in the aged polar bear [see (33)].

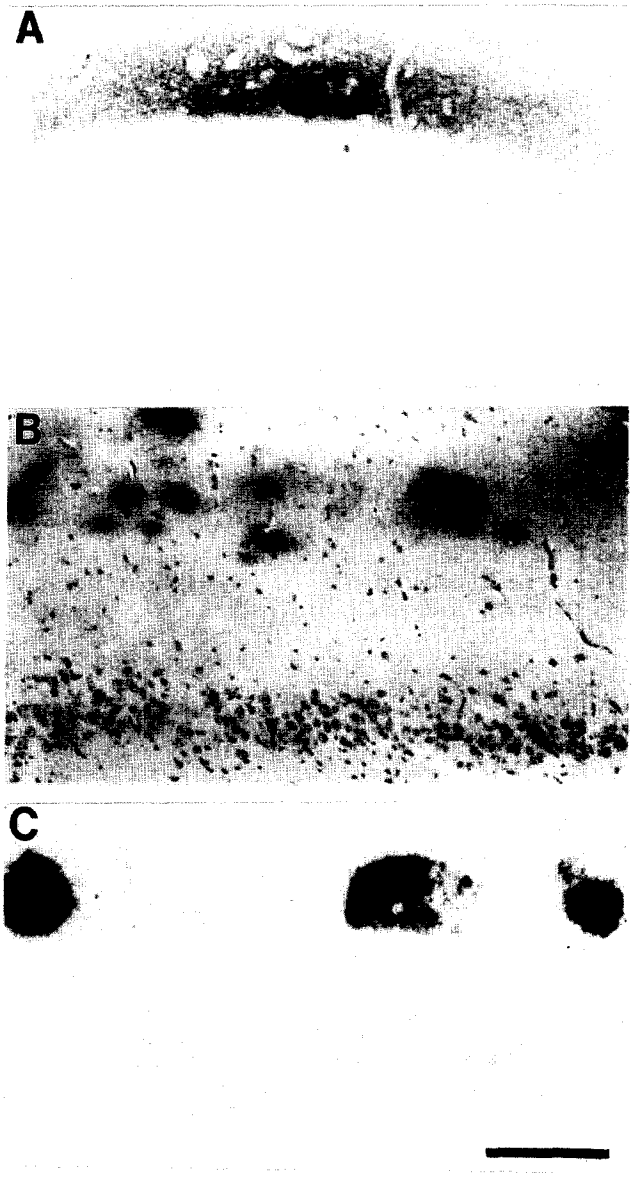

FIG. 7. β-Amyloid deposits in the dentate gyrus outer molecular layer of the dog, polar bear, and human brain. The 10D5 antibody immunolabeled Aβ deposits in the dentate gyrus outer molecular layer in each species examined. In the dog (A), Aβ was present as a faint diffuse cloud in the outer molecular layer. In the polar bear (B), the deposits were amorphous, although distinct plaques were apparent. This section was also stained with hematoxylin. In the brain of a nondemented, 84-year old, female well-defined Aβ deposits were evident (C). In each case the plaques were also stained by the 7A3 antibody, but not by anti-Aβ40 (not shown). Scale bar = 200 μm (C).

DISCUSSION

This study compared the C-terminus of β-amyloid deposits in aged beagles and polar bears with those in the aged normal, and AD human brain. In all three species, diffuse plaques were positively immunostained with an antibody (7A3) that recognizes Aβ42(43), but not Aβ40. Polar bear and dog brain CVA contained both Aβ42(43) and Aβ40. However, some CVA deposits in the polar bear were preferentially labeled by anti-Aβ42(43). Naslund and colleagues (27) have reported that Aβ42 is the principal Aβ variant present in nondemented elderly controls. Ihara and coworkers (14) and Cole and colleagues (20) have observed that all senile plaques are positively labeled with anti-42(43), while only a subset of these plaques are Aβ40 immunopositive. Thus, the results of this study extend those previously reported in human brain and demonstrate that Aβ42(43) is the initially deposited isoform in diffuse plaques in several mammalian species. The results further suggest that Aβ42(43) is initially deposited in CVA.

Mature plaques, which contain Aβ40, were not observed in the aged dog or polar bear. These plaques are thought to evolve from diffuse plaques, based on temporal events in the development of AD-like pathology in individuals with Down syndrome (22). Alternatively, the formation of each plaque type may involve unique mechanisms, with CVA possibly contributing to neuritic plaques (38). In the aged mammals, the presence of CVA deposits and absence of neuritic plaques support distinctive plaque developmental mechanisms. In addition, the brain regions exhibiting CVA deposits were often spatially separated from diffuse plaques. Moreover, some animals had diffuse plaques without CVA, arguing against a relationship between the two lesions.

A polar bear (age 28), has previously been reported to have senile plaques, but not neurofibrillary tangles (7,36). However, the senile plaque designation was based upon neurites immunostained with an anti-neurofilament antibody. Plaque-associated neurites were not labeled by Alz-50, anti-paired helical filament, or anti-tau antibodies (7,36). Neurofibrillary tangles, in the absence of senile plaques, have been observed in an Asiatic brown bear (7). The NFTs were immunoreactive with Alz-50, antibodies against phosphorylated neurofilament epitopes, and an antibody that recognizes PHFs and tau. Electron microscopy demonstrated that the tangles contained straight 10–16 nm filaments, but not paired helical filaments. In the present study, polar bear tangles were detected with

both modified Bielschowsky silver stain and the PHF-1 antibody against phosphorylated tau. Plaque dystrophic neurites were not observed with either stain. The Aβ deposits in the aged polar bear brain are, therefore, regarded as diffuse plaques.

Senile plaques have been reported in aged dogs (38,39,49), whereas other studies suggest the plaques are entirely of the diffuse type (3,8,11,33). Many of the senile plaque designations were described prior to diffuse plaque characterization. Reexamination of the reports suggests that these plaques are of the diffuse type. For example, in a study by Wisniewski and colleagues (49), the lack of a neuritic reaction to the amyloid deposits is noted. Additionally, Shimada's plaque characterization is solely based on β-amyloid immunostaining (38,39). The mature plaque forms described by this group appear similar to vascular or perivascular β-amyloid deposits. The prevalence of diffuse plaques observed in this study, along with cerebrovascular β-amyloid deposits, is consistent with previous reports of amyloid deposition in aged dogs.

Aβ deposits in the dentate gyrus outer molecular layer were observed in the aged dog, bear, and human brain. The neurons that project to this region are located in layer II of the entorhinal cortex and are the first to exhibit neurofibrillary pathology (4,46). Although the relationship between the two lesions is unclear, the presence of Aβ in the dentate gyrus outer molecular layer in the aged beagle dog brain, but lack of pathology in entorhinal cortex, illustrates that Aβ deposition precedes (or occurs in the absence of) neurofibrillary pathology. The results further suggest that the dentate gyrus outer molecular layer is one of the earliest sites of Aβ deposition in the aged mammalian brain.

Although diffuse Aβ deposits in the aged beagle dog, polar bear, and human brain are each labeled with antibodies against Aβ42(43), they are morphologically distinct. The deposits in the dog brain are faint and cloud-like, whereas those in the human brain are more compact and intensely immunostained. Aβ deposits in the polar bear appear to represent an intermediate stage. Transgenic mice overexpressing V717F β-amyloid precursor protein exhibit β-amyloid deposits at the dentate gyrus outer molecular layer (10), which resemble those observed in the polar bear. In both of these models, amyloid clouds and aggregates are apparent. The cause of the species differences is uncertain, but could reflect an age-related increase in βAPP expression, inability to clear extracellular β-amyloid, or species differences in the proteins associated with Aβ, which may promote Aβ aggregation. Aβ aggregation promoting factors include α1-antichymotrypsin (1), apolipoprotein E (26,42), heparan sulfate proteoglycan (40) and non-Aβ component (45). It is also possible that the differences reflect case-to-case variability among individual animals.

Overall, the processes involved in age-related Aβ deposition appear to be similar among the examined mammalian species. The results obtained in the animal models closely resemble Aβ deposition in the aged human brain and the early stages of Alzheimer pathology observed in individuals with Down syndrome; Aβ42(43) immunopositive diffuse plaques precede the appearance of Aβ40 immunopositive mature plaques and neurofibrillary tangles. The results further suggest that diffuse plaques begin as a widespread deposit of β-amyloid that gradually coalesces into a more compact, spherical mass. In the aged beagle dog and aged polar bear, the lack of extensive AD pathology suggests that Aβ42 deposition may be necessary but not sufficient to trigger AD. The data illustrate that these aged mammals serve as useful models of the initial stages of β-amyloid deposition.

ACKNOWLEDGEMENTS

We thank Athena Neurosciences for the 10D5 antibody, Dr. Sharon Greenberg for the PHF-1 antibody, and Dr. Steven Estus for helpful discussions and comments on the manuscript. This work was supported by NIH Grants AG9009 and AG1125 (G.M.C.); AG10678 (J.W.G.); AG10678 (M.J.R.); AG05144 and AG05119 (W.R.M.); AG09862 and AG00553 (D.A.S.).

REFERENCES

1. Abraham, C. R.; Selkoe, D. J.; Potter, H. Immunochemical identification of the serine protease inhibitor α1-antichymotrypsin in the brain amyloid deposits of Alzheimer's disease. Cell 52:487–501; 1988.
2. Allsop, D.; Haga, S. I.; Haga, C.; Ikeda, S. I.; Mann, D. M.; Ishii, T. Early senile plaques in Down's syndrome brains show a close relationship with cell bodies of neurons. Neuropathol. Appl. Neurobiol. 15:531–542; 1989.
3. Ball, M. J.; MacGregor, J.; Fyfe, I. M.; Rapoport, S. I.; London, E. D. Paucity of morphological changes in the brains of ageing beagle dogs: Further evidence that Alzheimer lesions are unique for primate central nervous system. Neurobiol. Aging. 4:127–131; 1983.
4. Braak, H.; Braak, E. Neuropathological stageing of Alzheimer-related changes. Acta Neuropathol. (Berl.) 82:239–259; 1991.
5. Burdick, D.; Soreghan, B.; Kwon, M.; Kosmoski, J.; Knauer, M.; Henschen, A.; Yates, J.; Cotman, C.; Glabe, C. Assembly and aggregation properties of synthetic Alzheimer's A4/beta amyloid peptide analogs. J. Biol. Chem. 267:546–554; 1992.
6. Conn, K. J.; Papastoitsis, G.; Meckelein, B.; Abraham, C. R. Identification of full length β-amyloid precursor protein in human neuronal and nonneuronal cell culture supernatant: A possible extracellular source for the generation of Aβ. Amyloid: Int. J. Clin. Invest. 1:232–239; 1994.
7. Cork, L. C.; Powers, R. E.; Selkoe, D. J.; Davies, P.; Geyer, J. J.; Price, D. L. Neurofibrillary tangles and senile plaques in aged bears. J. Neuropathol. Exp. Neurol. 47:629–641; 1988.
8. Cummings, B. J.; Su, J. H.; Cotman, C. W.; White, R.; Russell, M. J. Beta-amyloid accumulation in aged canine brain: A model of early plaque formation in Alzheimer's disease. Neurobiol. Aging 14:547–560; 1993.
9. Dickson, D. W.; Crystal, H. A.; Mattiace, L. A.; Masur, D. M.; Blau, A. D.; Davies, P.; Yen, S. H.; Aronson, M. K. Identification of normal and pathologic aging in prospectively studied nondemented elderly humans. Neurobiol. Aging 13:179–189; 1992.
10. Games, D.; Adams, D.; Alessandrini, R.; Barbour, R.; Berthelette, P.; Blackwell, C.; Carr, T.; Clemens, J.; Donaldson, T.; Gillespie, F.; Guido, T.; Hagopian, S.; Johnson-Wood, K.; Khan, K.; Lee, M.; Leibowitz, P.; Liebergurg, I.; Little, S.; Masliah, E.; McConlogue, L.; Montoya-Azvala, M.; Mucke, L.; Paganini, L.; Penniman, E.; Power, M.; Schenk, D.; Seubert, P.; Snyder, B.; Soriano, F.; Tan, H.; Vitale, J.; Wadsworth, S.; Wolozin, B.; Zhao, J. Alzheimer-type neuropathology in transgenic mice overexpressing V717F β-amyloid precursor protein. Nature 373:523–527; 1995.
11. Giaccone, G.; Verga, L.; Finazzi, M.; Pollo, B.; Tagliavini, F.; Frangione, B.; Bugiani, O. Cerebral preamyloid deposits and congophilic angiopathy in aged dogs. Neurosci. Lett. 114:178–183; 1990.
12. Greenberg, S. G.; Davies, P.; Schein, J. D.; Binder, L. I. Hydrofluoric acid-treated tau PHF proteins display the same biochemical properties as normal tau. J. Biol. Chem. 267:564–569; 1992.
13. Iwatsubo, T.; Mann, D. M. A.; Odaka, A.; Suzuki, N.; Ihara, Y. Amyloid β protein (Aβ) deposition: Aβ42(43) precedes Aβ40 in Down syndrome. Ann. Neurol. 37:294–299; 1995.
14. Iwatsubo, T.; Odaka, A.; Suzuki, N.; Mizusawa, H.; Nukina, N.; Ihara, Y. Visualization of Aβ42(43) and Aβ40 in senile plaques with end-specific Aβ monoclonals: Evidence that an initially deposited species is Aβ42(43). Neuron 13:45–64; 1994.
15. Jarrett, J. T.; Berger, E. P.; Lansbury, P. T. J. The carboxy terminus of the β amyloid protein is critical for the seeding of amyloid formation: Implications for the pathogenesis of Alzheimer's disease. Biochemistry 32:4693–4697; 1993.
16. Johnstone, E. M.; Chaney, M. O.; Norris, F. H.; Pascual, R.; Little, S. P. Conservation of the sequence of the Alzheimer's disease amyloid peptide in dog, polar bear and five other mammals by cross-species

polymerase chain reaction analysis. Brain Res. Mol. Brain Res. 10: 299–305; 1991.
17. Khachaturian, Z. S. Diagnosis of Alzheimer's disease. Arch. Neurol. 42:1097–1105; 1985.
18. Kida, E.; Golabek, A. A.; Wisniewski, T.; Wisniewski, K. E. Regional differences in apolipoprotein E immunoreactivity in diffuse plaques in Alzheimer's disease brain. Neurosci. Lett. 167:73–76; 1994.
19. Kitamoto, T.; Ogomori, K.; Tateishi, J.; Prusiner, S. B. Formic acid pretreatment enhances immunostaining of cerebral and systemic amyloids. Lab. Invest. 57:230–236; 1987.
20. Mak, K.; Yang, F.; Vinters, H. V.; Frautschy, S. A.; Cole, G. M. Polyclonals to β-amyloid (1–42) identify most plaque and vascular deposits in Alzheimer cortex, but not striatum. Brain Res. 667:138–142; 1994.
21. Mandybur, T. I. The incidence of cerebral amyloid angiopathy in Alzheimer's disease. Neurology 25:120; 1975.
22. Mann, D. M.; Brown, A.; Prinja, D.; Davies, C. A.; Landon, M.; Masters, C. L.; Beyreuther, K. An analysis of the morphology of senile plaques in Down's syndrome patients of different ages using immunocytochemical and lectin histochemical techniques. Neuropathol. Appl. Neurobiol. 15:317–329; 1989.
23. Martin, L. J.; Pardo, C. A.; Cork, L. C.; Price, D. L. Synaptic pathology and glial responses to neuronal injury precede the formation of senile plaques and amyloid deposits in the aging cerebral cortex. Am. J. Pathol. 145:1358–1381; 1994.
24. Miller, D. L.; Papayannopoulos, I. A.; Styles, J.; Bobin, S. A.; Lin, Y. Y.; Biemann, K.; Iqbal, K. Peptide compositions of the cerebrovascular and senile plaque core amyloid deposits of Alzheimer's disease. Arch. Biochem. Biophys. 301:41–52; 1993.
25. Mori, H.; Takio, K.; Ogawara, M.; Selkoe, D. J. Mass spectrometry of purified amyloid β protein in Alzheimer's disease. J. Biol. Chem. 267:17082–17086; 1992.
26. Namba, Y.; Tomonaga, M.; Kawasaki, H.; Otomo, E.; Ikeda, K. Apolipoprotein E immunoreactivity in cerebral amyloid deposits and neurofibrillary tangles in Alzheimer's disease and kuru plaque amyloid in Creutzfeldt-Jakob disease. Brain Res. 541:163–166; 1991.
27. Näslund, J.; Schierhorn, A.; Hellman, U.; Lannfelt, L.; Roses, A. D.; Tjernberg, L. O.; Silberring, J.; Gandy, S. E.; Winblad, B.; Greengard, P.; Norstedt, C.; Terenius, L. Relative abundance of Alzheimer A beta amyloid peptide variants in Alzheimer disease and normal aging. Proc. Natl. Acad. Sci. USA 91:8378–8382; 1994.
28. Pike, C. J.; Burdick, D.; Walencewicz, A. J.; Glabe, C. G.; Cotman, C. W. Neurodegeneration induced by beta-amyloid peptides in vitro: The role of peptide assembly state. J. Neurosci. 13:1676–1687; 1993.
29. Pike, C. J.; Walencewicz, A. J.; Glabe, C. G.; Cotman, C. W. Aggregation-related toxicity of synthetic beta-amyloid protein in hippocampal cultures. Eur. J. Pharmacol. 207:367–368; 1991.
30. Poduri, A.; Gearing, M.; Rebeck, G. W.; Mirra, S. S.; Tigges, J.; Hyman, B. T. Apolipoprotein E4 and beta amyloid in senile plaques and cerebral blood vessels of aged rhesus monkeys. Am. J. Pathol. 144: 1183–1187; 1994.
31. Roher, A. E.; Lowenson, J. D.; Clarke, S.; Wolkow, C.; Wang, R.; Cotter, R. J.; Reardon, I. M.; Zürcher-Neely, H. A.; Heinrikson, R. L.; Ball, M. J.; Greenberg, B. D. Structural alterations in the peptide backbone of β-amyloid core protein may account for its deposition and stability in Alzheimer's disease. J. Biol. Chem. 268:3072–3083; 1993.
32. Rozemuller, H. M.; Eikelenboom, P.; Stam, F. C.; Beyreuther, K.; Masters, C. L. A4 protein in Alzheimer's disease: Primary and secondary cellular events in extracellular amyloid depostion. J. Neuropathol. Exp. Neurol. 48:674–691; 1989.
33. Russell, M. J.; White, R.; Patel, E.; Markesbery, W. R.; Watson, C. R.; Geddes, J. W. Familial influence on plaque formation in the beagle brain. Neuroreport 3:1093–1096; 1992.
34. Saido, T. C.; Iwatsubo, T.; Mann, D. M. A.; Shimada, H.; Ihara, Y.; Kawashima, S. Dominant and differential deposition of distinct β-amyloid species, AβN3(pE), in senile plaques. Neuron 14:457–486; 1995.
35. Selkoe, D. J. Normal and abnormal biology of the beta-amyloid precursor protein. Annu. Rev. Neurosci. 17:489–517; 1994.
36. Selkoe, D. J.; Bell, D. S.; Podlisny, M. B.; Price, D. L.; Cork, L. C. Conservation of brain amyloid proteins in aged mammals and humans with Alzheimer's disease. Science 235:873–877; 1987.
37. Seubert, P.; Vigo, P. C.; Esch, F.; Lee, M.; Dovey, H.; Davis, D.; Sinha, S.; Schlossmacher, M.; Whaley, J.; Swindlehurst, C.; McCormack, R.; Wolfert, R.; Selkoe, D.; Lieberburg, I.; Schenk, D. Isolation and quantification of soluble Alzheimer's β-peptide from biological fluids. Nature 359:325–327; 1992.
38. Shimada, A.; Kuwamura, M.; Awakura, T.; Umemura, T.; Takada, K.; Ohama, E.; Itakura, C. Topographic relationship between senile plaques and cerebrovascular amyloidosis in the brain of aged dogs. J. Vet. Med. Sci. 54:137–144; 1992.
39. Shimada, A.; Kuwamura, M.; Umemura, T.; Takada, K.; Ohama, E.; Itakura, C. Modified Bielschowsky and immunohistochemical studies on senile plaques in aged dogs. Neurosci. Lett. 129:25–38; 1991.
40. Snow, A. D.; Mar, H.; Nochlin, D.; Kimata, K.; Kato, M.; Suzuki, S.; Hassell, J.; Wight, T. N. The presence of heparan sulfate proteoglycans in the neuritic plaques and congophilic angiopathy in Alzheimer's disease. Am. J. Pathol. 133:456–463; 1988.
41. Soto, C.; Branes, M. C.; Alvarez, J.; Inestrosa, N. C. Structural determinants of the Alzheimer's amyloid beta-peptide. J. Neurochem. 63: 1191–1198; 1994.
42. Strittmatter, W. J.; Saunders, A. M.; Schechel, D.; Pericak-Vance, M.; Enghild, J.; Salvesen, G. S.; Roses, A. D. Apoliprotein E: High-avidity binding to β-amyloid and increased frequency of type 4 allele in late-onset familial Alzheimer disease. Proc. Natl. Acad. Sci. USA 90:1977–1981; 1993.
43. Suzuki, N.; Cheung, T. T.; Cai, X. D.; Odaka, A.; Otvos, L. J.; Eckman, C.; Golde, T. E.; Younkin, S. G. An increased percentage of long amyloid β protein secreted by familial amyloid β protein precursor (βAPP717) mutants. Science 264:1336–1340; 1994.
44. Tomlinson, B. E.; Blessed, G.; Roth, M. Observations on the brains of nondemented old people. J. Neurol Sci. 7:331–356; 1968.
45. Uéda, K.; Fukushima, H.; Masliah, E.; Xia, Y.; Iwai, A.; Yoshimoto, M.; Otero, D. A. C.; Kondo, J.; Ihara, Y.; Saitoh, T. Molecular cloning of a novel component of amyloid in Alzheimer's disease. Proc. Natl. Acad. Sci. USA 90:11282–11286; 1993.
46. Van Hoesen, G. W.; Hyman, B. T. Hippocampal formation: Anatomy and the patterns of pathology in Alzheimer's disease. In: Storm-Mathisen, J.; Zimmer, J; Ottersen, O. P., eds. Progress in brain research. New York: Elsevier; 1990.
47. Vinters, H. V. Cerebral amyloid angiopathy and Alzheimer's disease: Two entities or one? J. Neurol Sci. 112:1–3; 1992.
48. Walker, L. C.; Price, D. L.; Voytko, M. L.; Schenk, D. B. Labeling of cerebral amyloid in vivo with a monoclonal antibody. J. Neuropathol. Exp. Neurol. 53:377–383; 1994.
49. Wisniewski, H.; Johnson, A. B.; Raine, C. S.; Kay, W. J.; Terry, R. D. Senile plaques and cerebral amyloidosis in aged dogs. A histochemical and ultrastructural study. Lab. Invest. 23:287–296; 1970.
50. Wisniewski, H. M.; Terry, M. D. Reexamination of the pathogenesis of the senile plaque. In: Zimmerman, H. M., ed. Progress in Neuropathology. New York, NY: Grune & Stratton, Inc; 1973;1–26.
51. Yamamoto, T.; Hirano, A. A comparative study of modified Bielschowsky, Bodian and thioflavin S stains on Alzheimer's neurofibrillary tangles. Neuropathol. Appl. Neurobiol. 12:3–9; 1986.
52. Yang, F.; Mak, K.; Vinters, H. V.; Frautschy, S. A.; Cole, G. M. Monoclonal antibody to the C-terminus of β-amyloid. Neuroreport 5:2117–2120; 1994.
53. Younkin , S. G. Evidence that Aβ42 is the real culprit in Alzheimer's Disease. Ann. Neurol. 37:287–288; 1995.